

2014 Wolff Award Paper

The Relation Between Migraine, Typical Migraine Aura and “Visual Snow”

Christoph J. Schankin, MD; Farooq H. Maniyar, MD; Till Sprenger, MD; Denise E. Chou, MD;
Michael Eller, MD; Peter J. Goadsby, MD, PhD

Objective.—To assess the relationship between the phenotype of the “visual snow” syndrome, comorbid migraine, and typical migraine aura on a clinical basis and using functional brain imaging.

Background.—Patients with “visual snow” suffer from continuous TV-static-like tiny flickering dots in the entire visual field. Most patients describe a syndrome with additional visual symptoms of the following categories: palinopsia (“afterimages” and “trailing”), entoptic phenomena arising from the optic apparatus itself (floaters, blue field entoptic phenomenon, photopsia, self-light of the eye), photophobia, nyctalopia (impaired night vision), as well as the non-visual symptom tinnitus. The high prevalence of migraine and typical migraine aura in this population has led to the assumption that “visual snow” is caused by persistent migraine aura. Due to the lack of objective measures, alternative diagnoses are malingering or a psychogenic disorder.

Methods.—(1) The prevalence of additional visual symptoms, tinnitus, and comorbid migraine as well as typical migraine aura was assessed in a prospective semi-structured telephone interview of patients with “visual snow.” Correlations were calculated using standard statistics with $P < .05$ being considered statistically significant. (2) Areas with increased brain metabolism in a group of “visual snow” patients in comparison to healthy controls were identified using [^{18}F]-2-fluoro-2-deoxy-D-glucose positron emission tomography and statistical parametric mapping (SPM8 with whole brain analysis; statistical significance was defined by $P < .001$ uncorrected for multiple comparisons).

Results.—(1) Of 120 patients with “visual snow,” 70 patients also had migraine and 37 had typical migraine aura. Having comorbid migraine was associated with an increased likelihood of having palinopsia (odds ratio [OR] 2.8; $P = .04$ for “after-images” and OR 2.6; $P = .01$ for “trailing”), spontaneous photopsia (OR 2.9; $P = .004$), photophobia (OR 3.2; $P = .005$), nyctalopia (OR 2.7; $P = .01$), and tinnitus (OR 2.9; $P = .006$). Typical migraine aura was associated with an increased likelihood of spontaneous photopsia (OR 2.4; $P = .04$). (2) After adjusting for typical migraine aura, comparison of 17 “visual snow” patients with 17 age and gender matched controls showed brain hypermetabolism in the right lingual gyrus (Montreal Neurological Institute coordinates 16-78-5; $k_E = 101$; $Z_E = 3.41$; $P < .001$) and the left cerebellar anterior lobe adjacent to the left lingual gyrus (Montreal Neurological Institute coordinates -12-62-9; $k_E = 152$; $Z_E = 3.28$; $P = .001$).

Conclusions.—Comorbid migraine aggravates the clinical phenotype of the “visual snow” syndrome by worsening some of the additional visual symptoms and tinnitus. This might bias studies on “visual snow” by migraineurs offering study participation more likely than non-migraineurs due to a more severe clinical presentation. The independence of entoptic phenomena from comorbid migraine indicates “visual snow” is the main determinant. The hypermetabolic lingual gyrus confirms a brain

From the Department of Neurology, University of California, San Francisco, CA, USA (C.J. Schankin, D.E. Chou, M. Eller, and P.J. Goadsby); Headache Group, NIHR-Wellcome Trust Clinical Research Facility, King’s College London, London, UK (C.J. Schankin and P.J. Goadsby); Department of Neurology, University of Munich Hospital – Großhadern, Munich, Germany (C.J. Schankin); Department of Neurology, The Royal London Hospital (Barts and the London NHS Trust), London, UK (F.H. Maniyar); Basildon and Thurrock University Hospitals NHS Foundation Trust, Nethermayne, UK (F.H. Maniyar); Department of Neurology, University Hospital Basel, Basel, Switzerland (T. Sprenger); Division of Neuroradiology, University Hospital Basel, Basel, Switzerland (T. Sprenger).

Address all correspondence to P.J. Goadsby, Wellcome Foundation Building, King’s College Hospital, London SE5 9PJ, UK, email: peter.goadsby@kcl.ac.uk

Accepted for publication April 11, 2014.

dysfunction in patients with “visual snow.” The metabolic pattern differs from interictal migraine with some similarities to migrainous photophobia. The findings support the view that “visual snow,” migraine, and typical migraine aura are distinct syndromes with shared pathophysiological mechanisms that need to be addressed in order to develop rational treatment strategies for this disabling condition.

Key words: visual snow, migraine, aura, [¹⁸F]-2-fluoro-2-deoxy-D-glucose positron emission tomography

Abbreviations: OR odds ratio, VS visual snow, [¹⁸F]-FDG PET [¹⁸F]-2-fluoro-2-deoxy-D-glucose positron emission tomography

(*Headache* 2014;54:957-966)

Patients with “visual snow” (VS) describe a visual disturbance that consists of tiny dynamically flickering dots in the entire visual field resembling the “static” or “snow” of a badly tuned analogue television. The symptoms are continuous and can persist over years. Persistent visual disturbance is mentioned sporadically in the literature without larger systematic studies.¹⁻³ Patients are often diagnosed as having persistent migraine aura, malingering, or psychogenic disorder because objective measures for the condition are not available to date. A recent study of a substantial cohort of subjects with VS confirmed that the visual disturbance is often associated with migraine and migraine aura. However, not every patient with VS has a history of migraine. Further, VS starts only rarely with migraine aura, and the phenotypical description as well as the clinical course of VS by no means resembles typical migraine aura, which is

in general homonymous, often presents with moving zigzag lines, and typically lasts less than 60 minutes. This suggests that VS is a unique condition different from migraine aura.^{4,6} Importantly, VS should be seen as a syndrome since it is almost always associated with additional visual complaints including palinopsia, entoptic phenomena that arise from the optic apparatus itself (ie, floaters, blue field entoptic phenomenon, self-light of the eye and photopsia),⁷ poor night vision (nyctalopia), and photophobia. A large proportion of VS patients has bilateral continuous tinnitus.⁵

To investigate the role of migraine and typical migraine aura mechanisms underlying VS, we sought to assess whether the presence of migraine or aura is associated with different phenotype of the *VS syndrome*. We prospectively recorded accompanying visual and auditory symptoms in a large cohort of

Conflict of Interest: C.J.S. has received an educational grant from Allergan to attend the 1st International Headache Academy meeting.

F.H.M has received an educational grant from Allergan to attend the 1st International Headache Academy meeting. He further received compensation for lectures by Menarini and for serving on the advisory board for Electrocore.

T.S. has received no personal compensation. His employer, the University Hospital Basel, has received compensation for his serving on scientific advisory boards or speaking fees for Actelion, ATI, Allergan, Biogen Idec, Genzyme, Jansen, Mitsubishi Pharma Europe, Novartis, and Teva. None of these related to the current work.

D.C. – None.

M.E. – None.

P.J.G. is on Advisory Boards for Allergan, Colucid, MAP Pharmaceuticals, Merck, Sharpe and Dohme, eNeura, Autonomic Technologies Inc, Electrocore, Eli-Lilly, Medtronic, Artea, AlderBio, and BristolMyerSquibb. He has consulted for Pfizer, Impax, Zosano, and Dr. Reddy, and has been compensated for expert legal testimony. He has grant support from Allergan, Amgen, MAP, and MSD. He has received honoraria for editorial work from Journal Watch Neurology and for developing educational materials and teaching for the American Headache Society.

Funding:

The study was supported by Eye on Vision Foundation (<http://www.eyeonvision.org/>).

C.J.S. was supported by the German Research Foundation (SCHA 1676/1-1).

patients with VS and correlated these symptoms with comorbid migraine and typical migraine aura. To assess potential pathophysiological correlates, we further studied brain metabolism in patients with the hypothesis that VS is associated with regional hypermetabolism distinct from previous findings in migraine.^{8,9}

Clinical data of a subgroup of the study population have been previously presented in a report on the detailed phenotype⁵ and in preliminary form.^{10,11}

SUBJECTS AND METHODS

The study was approved by the Institutional Review Board (# 11-07270 and # 11-07431) and the radiation safety committee (58605-RU-04-URH) of the University of California, San Francisco. Patients were recruited via advertisements in social media with the support of a self-help group on VS (Eye on Vision Foundation; <http://www.eyeonvision.org/>). After being contacted by the patient, eligibility was assessed during telephone interviews.

Clinical Data.—Telephone Interview.—After being approached by the patient, verbal consent was obtained and subjects with self-suspected VS underwent a semi-structured telephone interview. The following items were covered during the interview:

1. Demographics (age, gender) and handedness.
2. Patients were asked to describe their current visual symptoms in their own words. Based on that information and additional open questions, a diagnosis of VS was made and associated visual symptoms were recorded as described recently.¹⁰ In brief, VS was defined as dynamic, continuous, tiny dots in the entire visual field (similar to “TV static” or “TV snow”) lasting longer than 3 months (criterion A).⁵ Other symptoms were palinopsia (“after-images” and “trailing” of moving objects), entopic phenomena (phenomena arising from the structure of the visual system itself including (1) excessive floaters in both eyes; (2) excessive blue field entoptic phenomenon, ie, uncountable little gray/white/black dots or rings shooting over the visual field in both eyes when looking at homogeneous bright surfaces, such as the blue sky; (3) self-light of the eye, ie, colored waves or clouds when closing

the eyes in the dark; and (4) spontaneous photopsia, ie, bright flashes of light),⁷ photophobia, and nyctalopia (impaired night vision). Due to its high prevalence in subjects with VS,⁵ the presence or history of tinnitus was also covered during the interview despite being a non-visual symptom.

3. Headache history was assessed according to the International Classification of Headache Disorders – 2nd edition.⁶ Migraine aura was only diagnosed when typical features were present, which are unilaterality (homonymous), development over 5 minutes, duration for less than 60 minutes, reversibility, zigzag lines, and scotoma.^{4,6}

Data Analysis.—SPSS (v20, IBM Corp., Armonk, NY, USA) was used for the statistical analysis of the clinical data. Standard descriptive statistics were applied. If appropriate, data are presented as mean \pm standard deviation. Nominal data were compared using chi-square or Fisher’s exact test, ratio data using *t*-test. Statistical significance was defined as $P < .05$.

Functional Brain Imaging.—All subjects participating in the positron emission tomography (PET) study gave written informed consent. Inclusion criterion was VS with at least 2 additional visual symptoms as defined previously.⁵ Control subjects did not have VS, associated visual symptoms, tinnitus, a history of frequent migraine attacks (more than 1 every 2 months), or of migraine aura. Exclusion criteria for both groups were ophthalmological pathology other than refraction anomalies, any lifetime history of intake of hallucinogenic drugs, and pregnancy in women. Each subject underwent a detailed personal interview with a focus on visual symptoms, migraine history including typical aura and general past medical history. On the scanning day, each subject had a fasting period of at least 6 hours prior to the acquisition of a high-resolution T1-weighted anatomical MR image (MPRAGE sequence) on a General Electric Signa HDxT 3.0 Tesla scanner (GE Healthcare, Fairfield, CT, USA). Afterwards, a [¹⁸F]-2-fluoro-2-deoxy-D-glucose PET ([¹⁸F]-FDG PET) scan was acquired using standard parameters, with injection of 10 mCi via an antecubital vein and 45 minutes distribution period in a dark room with eyes closed, on a

GE Discovery VCT PET/CT scanner (GE Healthcare) in three-dimensional (3D) mode with septa retracted. Images were reconstructed by 3D iterative reconstruction into 47 image planes (separation 3.27 mm) and into a 128 by 128 image matrix (pixel size: $2.1 \times 2.1 \text{ mm}^2$). The structural magnetic resonance imaging (MRI) was coregistered to the PET using SPM8 (Wellcome Department of Imaging Neuroscience, <http://www.fil.ion.ucl.ac.uk/spm>). The coregistered MRI was automatically segmented into gray matter, white matter, and cerebrospinal fluid and normalized into standard stereotaxic space. The spatial normalization parameters from this step were applied to spatially normalize the PET image. Final voxel size was $2 \times 2 \times 2 \text{ mm}^3$. PET images were then smoothed with a Gaussian Kernel of 12 mm full-width at half maximum. The group of VS patients was compared with controls using a 2-sample *t*-test with masking of non-brain tissue (whole brain explicit mask generated with WFU PickAtlas from Advanced Neuroscience Imaging Research Laboratory, Department of Radiology of Wake Forest University School of Medicine, <http://fmri.wfubmc.edu/>), and using proportional scaling. Due to the high prevalence of typical migraine aura in patients with VS,¹¹ the presence of migraine aura was used as a covariate of no interest. According to the clinical manifestation of VS, we suspected hypermetabolism in VS patients. We therefore assessed brain areas with *increased* metabolism in VS patients compared with controls in a voxel-wise fashion. In line with previous studies on migraine,^{12,13} we considered voxels reaching a significance threshold of $P < .001$ uncorrected for multiple comparisons to be significant.

RESULTS

Clinical Data.—Of the 142 patients who contacted the Headache Center at the University of California, San Francisco, 120 subjects (mean age 31 ± 12 years; 62 female) met criterion A for “visual snow,”⁵ ie, presence of dynamic, continuous, tiny dots in the entire visual field lasting longer than 3 months.

Additional Visual Symptoms.—Palinopsia with “afterimages” from stationary scenes was present in 84%, and with “trailing” in 58%. Excessive floaters were the most common entoptic phenomenon with a

Table 1.—Additional Symptoms in Patients With “Visual Snow”

	All Visual Snow Patients N = 120	
Palinopsia (“afterimages”)	101	84%
Palinopsia (“trailing”)	69	58%
Floaters	99	83%
Blue field entoptic phenomenon	91	76%
Self-light of the eye	64	53%
Spontaneous photopsia	64	53%
Photophobia	86	72%
Nyctalopia	76	63%
Tinnitus	77	64%

prevalence of 83%. Second most common was the blue field entoptic phenomenon (76%). Spontaneous photopsia and consistent self-light of the eye occurred in half of patients. About two thirds of patients had photophobia and nyctalopia. In addition to these visual symptoms, 64% of patients noted continuous bilateral and mainly high-pitched tinnitus (Table 1).

Association of Additional Symptoms With Migraine and Typical Migraine Aura.—The presence of migraine was associated with an increased prevalence of the additional symptoms palinopsia (odds ratio [OR] 2.8 for “afterimages” and OR 2.6 for “trailing”), spontaneous photopsia (OR 2.9), photophobia (OR 3.2), nyctalopia (OR 2.7), and tinnitus (OR 2.9). Spontaneous photopsia was more prevalent in patients with typical migraine aura (OR 2.4, Table 2).

Functional Brain Imaging.—Seventeen patients (10 female, mean age \pm standard deviation 31 ± 7 years) with VS and at least 2 additional visual symptoms were recruited for the imaging study. Seven had VS as long as they could remember. Mean age of onset in the remaining was 25 ± 8 years. Fourteen (82%) had a history of migraine. Five of those had migraine with typical aura, and 1 had typical migraine aura without history of migraine.⁶ All 3 patients without history of migraine had a positive family history of migraine. Besides headache, past medical history included depression, Graves’ disease, hypothyroidism, acne, and attention deficit hyperactivity syndrome, each present only in 1 subject. The current regular medication as well as the past medication

Table 2.—Correlations Between Additional Symptoms in Patients With “Visual Snow” and Comorbid Migraine and Typical Migraine Aura (Statistics: Chi-Square Test)

	Patients With “Visual Snow” N = 120							
	Migraine				Typical Migraine Aura			
	Yes n = 70	No n = 50	<i>P</i>	OR (95% CI)	Yes n = 37	No n = 83	<i>P</i>	OR (95% CI)
Palinopsia (“afterimages”)	63	38	.04	2.8 (1.0; 7.8)	34	67	.12	—
Palinopsia (“trailing”)	47	22	.01	2.6 (1.2; 5.5)	25	44	.14	—
Floaters	60	39	.27	—	30	69	.79	—
Blue field entoptic phenomenon	53	38	.97	—	28	63	.98	—
Self-light of the eye	38	26	.81	—	20	44	.92	—
Spontaneous photopsia	45	19	.004	2.9 (1.4; 6.2)	25	39	.04	2.4 (1.0; 5.3)
Photophobia	57	29	.005	3.2 (1.4; 7.2)	30	56	.13	—
Nyctalopia	51	25	.01	2.7 (1.2; 5.8)	26	50	.29	—
Tinnitus	52	25	.006	2.9 (1.3; 6.2)	27	50	.18	—

—, NA.

trials for VS are shown in Table 3. All subjects stated having normal ophthalmological exams except for some refraction anomalies. The 17 controls had the same age and gender distribution (10 female, 31 ± 7 years). Since history of migraine and typical migraine aura were exclusion criteria for controls, they differed significantly from VS patients in respect of history of migraine ($P < .001$, Fisher’s exact test) and history of typical migraine aura ($P = .02$, Fisher’s exact test).

The voxel-wise [^{18}F]-FDG PET group comparison evidenced hypermetabolism of the right lingual gyrus (Montreal Neurological Institute coordinates: 16-78-5; cluster size $k_E = 101$; $Z_E = 3.41$; $P < .001$) and a trend for the anterior lobe of the left cerebellum (Montreal Neurological Institute: -12-62-9; $k_E = 152$; $Z_E = 3.28$; $P = .001$) (Figure) in patients with VS when compared with healthy controls after adjusting for the presence of typical migraine aura.

DISCUSSION

“Visual snow” (VS) is a disabling disorder with patients complaining about TV-snow-like tiny flickering dots in the entire visual field. The symptoms can be continuous and might persist over years. In a recent study, almost all patients with VS had addi-

tional visual symptoms, such as palinopsia, entoptic phenomena (floaters, blue field entoptic phenomenon, and others), nyctalopia (impaired night vision), photophobia, and tinnitus suggesting that VS is likely a clinical syndrome.⁵ In our study population, the majority of patients with VS had comorbid migraine (58%), and 31% had typical migraine aura. This high comorbidity, when compared with the general population,¹⁴ has led to the assumption that VS might represent persistent migraine aura as often discussed in the initial case series,¹⁻³ although the clinical presentation is clearly different from typical migraine aura.⁵

Here, we sought to understand whether the VS syndrome manifests differently in patients with migraine or typical aura. For that, a cohort of VS patients was carefully phenotyped in respect to the clinical presentation and comorbidities. We found that VS patients, who also have migraine according to International Classification of Headache Disorders – 2nd edition⁶ had a significantly higher likelihood of having palinopsia, photophobia, nyctalopia, and tinnitus. Of the entoptic phenomena, ie, visual perceptions arising from the optic apparatus itself,⁷ only spontaneous photopsia was more prevalent in VS patients with migraine history, while floaters, blue

Table 3.—Current Regular Medication and Past Treatment Trials for “Visual Snow” in 17 VS Patients Who Took Part in the [¹⁸F]-FDG PET Study

	Current Medication	Medication for “Visual Snow”		
		Generic Name	Duration	Effect
1	—	—	—	—
2	—	Sertraline, fluoxetine	6 months	None
3	—	—	—	—
4	Dexlansoprazole, bupropion, zolpidem, topiramate, dicyclomine	—	—	None
5	Methimazole	Fluoxetine, verapamil, lamotrigine	—	None
	—	Sertraline	—	Worsening
6	—	Amitriptyline, propranolol	2 months	None
7	—	—	—	—
8	—	Naproxen	—	Improvement
	—	Sertraline, clonazepam	—	None
9	Throid (porcine), vitamin D, fexofenadine	—	—	None
10	—	—	—	—
11	—	—	—	—
12	—	—	—	—
13	Minocycline	—	—	None
14	—	—	—	—
15	—	—	—	—
16	—	—	—	—
17	—	—	—	—

—, no current medication and/or no medication tried for “visual snow” in the past.

field entoptic phenomenon, and self-light of the eye were equally distributed. Three major conclusions might be drawn from this: First, the presence of migraine might aggravate the manifestation of the VS syndrome by worsening some, but not all additional visual symptoms. Second, our study population was recruited via a self-help group, and it is possible that patients with a more severe clinical manifestation are more eager to participate in a research study. Therefore, a more severe manifestation of the VS syndrome in migraineurs indicates that the high prevalence of migraine in our VS study population might be subject to a selection bias suggesting that the relevance of migraine for VS pathophysiology might be overrated as well. In contrast, the presence of typical migraine aura, ie, the putative correlate of cortical spreading depression¹⁵ that presents with a homonymous, centrifugally moving scintillating scotoma shaped in zigzag lines,^{16,17} does not substantially alter the distribution of the additional visual symptoms in the VS syndrome. Typical migraine aura may thus not influ-

ence the VS phenotype suggesting that the high prevalence of aura is less subject to selection bias than migraine. Although VS is clearly not persistent migraine aura,⁵ typical migraine aura might share some pathophysiological background with the VS syndrome. Third, the impressive entoptic phenomena floaters, blue field entoptic phenomenon, and self-light of the eye are present in VS patients independently of a history of migraine, suggesting that these symptoms are probably not mediated or facilitated by a migrainous mechanism. In contrast, they might depend solely on the presence of VS.

Some of the additional visual symptoms in patients with VS can also be found in migraineurs. This might, at least in part, explain how a migrainous, but not typical migraine aura, comorbidity might potentiate these symptoms in VS patients. For migraineurs without VS, the higher prevalence of palinopsia when compared with healthy controls seems to be of minor relevance since it affects only 14.2% of the group and occurs only episodically.¹⁸

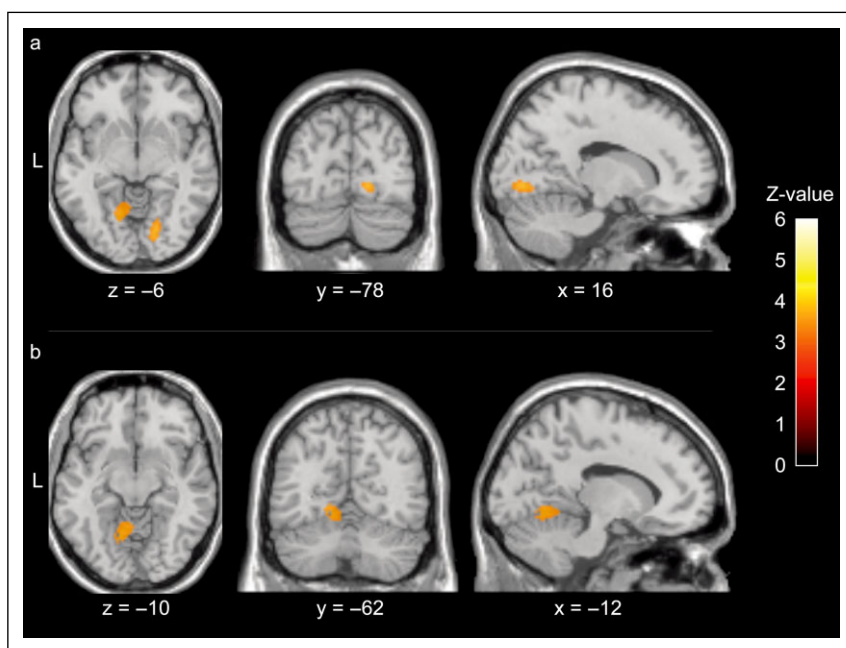


Figure.—When comparing the brain metabolism of patients with “visual snow” to healthy controls in [^{18}F]-FDG PET using a paired t -test in SPM8, the right lingual gyrus (in [a]; Montreal Neurological Institute 16-78-5; $k_E = 101$; $Z_E = 3.41$; $P < .001$) and the anterior lobe of the left cerebellum (in [b]; Montreal Neurological Institute -12-62-9; $k_E = 152$; $Z_E = 3.28$, $P = .001$) were metabolically more active in patients with “visual snow.” The figure was thresholded at $P \leq .001$.

However, this predisposition to palinopsia in migraineurs might perpetuate mechanisms of palinopsia in VS resulting in a higher prevalence and continuous presence.⁵ For the key migraine symptom photophobia,⁶ recent studies have suggested a pain-mediated increase in light sensitivity.¹⁹ In VS, such mechanism is unlikely due to the low prevalence of chronic headache in patients with *continuous* VS and photophobia.⁵ In contrast, photophobia as a symptom of the VS syndrome might be perpetuated by comorbid migraine in a non-pain-mediated manner. This is less clear for tinnitus, which is not a classical migrainous symptom²⁰ although migraine attack-associated episodes of tinnitus have been reported.²¹ Tinnitus could be interpreted as noise within the acoustic system. The similarity to “TV-snow,” ie, “TV-noise,” has previously led to the interpretation that tinnitus might be the clinical correlate of the affection of the acoustic system by VS-like mechanisms.⁵ In our study, tinnitus was also more prevalent in VS patients with comorbid migraine and thus behaved like the additional visual symptoms supporting that the VS syndrome might indeed include the non-visual symptom tinnitus.

In [^{18}F]-FDG PET, the right lingual gyrus and the anterior lobe of the left cerebellum were metabolically more active in patients with VS when compared with healthy controls. This first objective correlate of VS strongly suggests the VS syndrome is a neurological condition. This has important consequences for communication with patients, who have been frequently diagnosed as having a psychogenic disorder or as being malingerers. The relevance of the (trend) hypermetabolism of the left cerebellum is unclear. The cerebellum’s key function for vision is extraocular motility.²² Only little is known about its role in visual perception, but cerebellar disease has been associated with difficulties in depth perception²³ or with a phenomenon called upside-down vision.^{24,25} When analyzed visually, this area seems to extend laterally and rostrally to the left lingual gyrus (Figure) possibly reflecting the relatively low spatial resolution of PET. Such bilateral hypermetabolism in the lingual gyrus might be a signature of hyperactivity of the visual system in VS. Interestingly, the same area showed hyperperfusion in [^{15}O]-water PET during high luminous stimulation in migraineurs²⁶ and during low light stimulation in spontaneous

migraine attacks indicating relevance for the migrainous phenomenon photophobia.²⁷ To put our finding into a broader neurobiological context, it has to be stated that the lingual gyrus is also involved in visual memory²⁸ and different higher order functions of vision, such as the perception of color,²⁹ the identification of facial expressions of emotions,³⁰ or grapheme-color synesthesia.³¹ This broad involvement of the lingual gyrus in visual post-processing including photophobia during migraine attacks indicates that VS might also be a disorder of visual post-processing.

One limitation of the imaging part of the study is the higher prevalence of migraineurs in the VS group in comparison with the control group. This could potentially bias the results by showing an effect from migraine rather than from VS – or by “masking” VS correlates in PET by the presence of migraine in the VS group. To address this issue, future studies with pure VS patients without history of migraine or with migraineurs without VS as controls would be necessary. However, we believe that the hypermetabolism in our patients is VS related and not a migraine effect since not all subjects with VS had a history of migraine and, importantly, several recent studies were not able to show hypermetabolism in *interictal* migraineurs in comparison with controls despite including only migraineurs.^{8,9,32} In addition, it is unlikely the metabolism data were biased by the higher number of patients with history of migraine aura in the VS group since only one third of VS patients had comorbid aura. Further, the analysis was adjusted for migraine aura and none of our subjects had experienced an episode of typical migraine aura during the distribution period of the tracer or during the scanning.

CONCLUSION

In a substantial cohort of patients with the “visual snow” (VS) syndrome, migraine is associated with an increased prevalence of the additional symptoms of palinopsia, photopsia, photophobia, nyctalopia, and tinnitus suggesting a more severe phenotype, although not with entoptic phenomena. VS patients with migraine might thus be more interested in participating in studies on VS than patients without

migraine, creating a bias of migraine prevalence in such studies and an overestimation of the relevance of migraine for VS pathophysiology. In contrast to migraine, comorbidity of typical migraine aura did not alter the phenotype of the VS syndrome. The high prevalence of typical migraine aura in VS patients therefore is not associated with a worsening of the additional visual symptoms and thus not with an overestimation of aura prevalence in VS. This might indicate a pathophysiological overlap of VS and typical migraine aura despite the distinct clinical presentation. [¹⁸F]-FDG PET revealed an objective correlate for VS symptoms. The unique pattern of hypermetabolism in the lingual gyrus in patients with VS has not been shown for *interictal* migraineurs alone. VS is thus a syndrome distinct from migraine, although the hyperperfusion of this area *during* migrainous photophobia indicates a potential pathophysiological overlap of both conditions and possibly reflects the perpetuation of the additional visual symptoms in VS patients by comorbid migraine. Understanding this overlap in more detail will be crucial to develop treatment strategies for this disabling neurological disorder in the future.

Acknowledgments: We thank all patients who have taken part in the interview and the imaging study. Without the interest, participation, and dedication of the patients, this study would not have been possible. The study was supported by the self-help group for “visual snow” (Eye On Vision Foundation) by communicating the study to “visual snow” sufferers. Jan Hoffmann, MD, Department of Neurology, University of California, San Francisco, San Francisco, CA, USA, helped conduct the interviews.

STATEMENT OF AUTHORSHIP

Category 1

(a) Conception and Design

Christoph J. Schankin; Farooq H. Maniyar; Peter J. Goadsby

(b) Acquisition of Data

Christoph J. Schankin; Denise E. Chou; Michael Eller

(c) Analysis and Interpretation of Data

Christoph J. Schankin; Till Sprenger; Peter J. Goadsby

Category 2**(a) Drafting the Manuscript**

Christoph J. Schankin

(b) Revising It for Intellectual Content

Farooq H. Maniyar; Till Sprenger; Denise E. Chou; Michael Eller; Peter J. Goadsby

Category 3**(a) Final Approval of the Completed Manuscript**

Christoph J. Schankin; Farooq H. Maniyar; Till Sprenger; Denise E. Chou; Michael Eller; Peter J. Goadsby

REFERENCES

- Jager HR, Giffin NJ, Goadsby PJ. Diffusion- and perfusion-weighted MR imaging in persistent migrainous visual disturbances. *Cephalalgia*. 2005;25:323-332.
- Liu GT, Schatz NJ, Galetta SL, Volpe NJ, Skobieranda F, Kosmorsky GS. Persistent positive visual phenomena in migraine. *Neurology*. 1995;45:664-668.
- Wang YF, Fuh JL, Chen WT, Wang SJ. The visual aura rating scale as an outcome predictor for persistent visual aura without infarction. *Cephalalgia*. 2008;28:1298-1304.
- Eriksen MK, Thomsen LL, Olesen J. The Visual Aura Rating Scale (VARS) for migraine aura diagnosis. *Cephalalgia*. 2005;25:801-810.
- Schankin CJ, Maniyar FH, Digre KB, Goadsby PJ. "Visual snow" – A disorder distinct from persistent migraine aura. *Brain*. 2014;137:1419-1428.
- Headache Classification Committee of The International Headache Society. The International Classification of Headache Disorders: 2nd edition. *Cephalalgia*. 2004;24(Suppl. 1):9-160.
- Tyler CW. Some new entoptic phenomena. *Vision Res*. 1978;18:1633-1639.
- Aurora SK, Barrodale PM, Tipton RL, Khodavirdi A. Brainstem dysfunction in chronic migraine as evidenced by neurophysiological and positron emission tomography studies. *Headache*. 2007;47:996-1003.
- Kim JH, Kim S, Suh SI, Koh SB, Park KW, Oh K. Interictal metabolic changes in episodic migraine: A voxel-based FDG-PET study. *Cephalalgia*. 2010;30:53-61.
- Schankin CJ, Maniyar FH, Goadsby PJ. Field-testing the criteria for visual snow (positive persistent visual disturbance). *Headache*. 2012;52:898.
- Schankin CJ, Maniyar FH, Hoffmann J, Chou D, Goadsby PJ. Visual snow: A new disease entity distinct from migraine aura. *Neurology*. 2012;78:S36-006.
- Afridi SK, Giffin NJ, Kaube H, et al. A positron emission tomographic study in spontaneous migraine. *Arch Neurol*. 2005;62:1270-1275.
- Denuelle M, Fabre N, Payoux P, Chollet F, Geraud G. Hypothalamic activation in spontaneous migraine attacks. *Headache*. 2007;47:1418-1426.
- Lipton RB, Scher AI, Kolodner K, Liberman J, Steiner TJ, Stewart WF. Migraine in the United States: Epidemiology and patterns of health care use. *Neurology*. 2002;58:885-894.
- Hadjikhani N, Sanchez Del Rio M, Wu O, et al. Mechanisms of migraine aura revealed by functional MRI in human visual cortex. *Proc Natl Acad Sci U S A*. 2001;98:4687-4692.
- Hansen JM, Baca SM, Vanvalkenburgh P, Charles A. Distinctive anatomical and physiological features of migraine aura revealed by 18 years of recording. *Brain*. 2013;136:3589-3595.
- Lashley KS. Patterns of cerebral integration indicated by the scotoma of migraine. *Arch Neurol Psychiatry*. 1941;42:259-264.
- Belcastro V, Cupini LM, Corbelli I, et al. Palinopsia in patients with migraine: A case-control study. *Cephalalgia*. 2011;31:999-1004.
- Nosedá R, Kainz V, Jakubowski M, et al. A neural mechanism for exacerbation of headache by light. *Nat Neurosci*. 2010;13:239-245.
- Volcy M, Sheftell FD, Tepper SJ, Rapoport AM, Bigal ME. Tinnitus in migraine: An allodynic symptom secondary to abnormal cortical functioning? *Headache*. 2005;45:1083-1087.
- Kayan A, Hood JD. Neuro-otological manifestations of migraine. *Brain*. 1984;107:1123-1142.
- Voogd J, Schraa-Tam CK, van der Geest JN, De Zeeuw CI. Visuomotor cerebellum in human and nonhuman primates. *Cerebellum*. 2012;11:392-410.
- Maschke M, Gomez CM, Tuite PJ, Pickett K, Konczak J. Depth perception in cerebellar and basal ganglia disease. *Exp Brain Res*. 2006;175:165-176.
- Charles N, Froment C, Rode G, et al. Vertigo and upside down vision due to an infarct in the territory of the medial branch of the posterior inferior cerebellar artery caused by dissection of a vertebral artery. *J Neurol Neurosurg Psychiatry*. 1992;55:188-189.

25. Horga Hernandez A, Pujadas F, Purroy F, Delgado P, Huertas R, Alvarez-Sabin J. Upside down reversal of vision due to an isolated acute cerebellar ischemic infarction. *J Neurol*. 2006;253:953-954.
26. Bouilloche N, Denuelle M, Payoux P, Fabre N, Trotter Y, Geraud G. Photophobia in migraine: An interictal PET study of cortical hyperexcitability and its modulation by pain. *J Neurol Neurosurg Psychiatry*. 2010;81:978-984.
27. Denuelle M, Bouilloche N, Payoux P, Fabre N, Trotter Y, Geraud G. A PET study of photophobia during spontaneous migraine attacks. *Neurology*. 2011;76:213-218.
28. Roland PE, Gulyas B. Visual memory, visual imagery, and visual recognition of large field patterns by the human brain: Functional anatomy by positron emission tomography. *Cereb Cortex*. 1995; 5:79-93.
29. Zeki S, Watson JD, Lueck CJ, Friston KJ, Kennard C, Frackowiak RS. A direct demonstration of functional specialization in human visual cortex. *J Neurosci*. 1991;11:641-649.
30. Kitada R, Johnsrude IS, Kochiyama T, Lederman SJ. Brain networks involved in haptic and visual identification of facial expressions of emotion: An fMRI study. *Neuroimage*. 2010;49:1677-1689.
31. Rich AN, Williams MA, Puce A, et al. Neural correlates of imagined and synaesthetic colours. *Neuropsychologia*. 2006;44:2918-2925.
32. Niazi AK, Andelova M, Sprenger T. Is the migrainous brain normal outside of acute attacks? Lessons learned from psychophysical, neurochemical and functional neuroimaging studies. *Expert Rev Neurother*. 2013;13:1061-1067.